

Mycobacterial Infection after Cosmetic Procedure with Botulinum Toxin A

MARCELA SAEB-LIMA¹, GERARDO-VICTOR SOLIS-ARREOLA², ANGEL FERNANDEZ-FLORES³

ABSTRACT

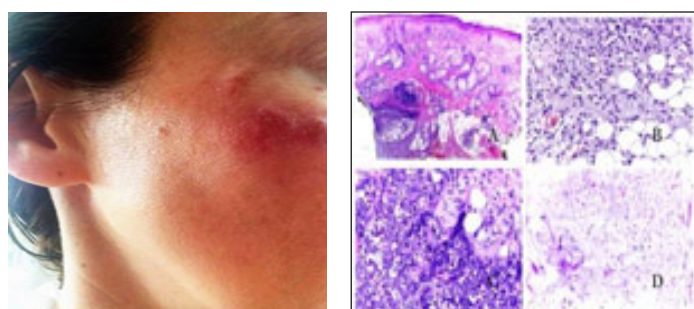
We report a case of mycobacterial infection at the sites of previous injections of botulinum toxin A in a 45-year-old woman. She presented with erythematous, swollen, warm, and tender plaques and nodules at the points of injection from which a biopsy was taken, demonstrating a deep dermal and hypodermal abscessified epithelioid granulomatous inflammatory infiltrate in which some acid-fast bacilli were identified with Ziehl-Neelsen and Fite-Faraco stains. The lesion was first treated with clarithromycin plus azithromycin, to which rifampicin was later added. A good therapeutic response was obtained.

Keywords: Botox, iatrogenic infection, Mycobacteria, Tuberculosis

CASE REPORT

A 45-year-old woman presented to the dermatology clinic complaining of lesions that had appeared soon after the injections of botulinum toxin A, at the sites of the injections. Gradually the lesions increased in size. The injections had been administered for cosmetic purposes five months before.

Physical examination showed erythematous, swollen, warm, and tender plaques and nodules at the points of injection: the procerus muscle zone and the pars externa of the orbicularis oculi muscle [Table/Fig-1]. One of the lesions was aspirated with a fine needle, obtaining a yellowish, purulent liquid, which was sent for microbiological culture with negative results for common bacteria and mycobacteria. An empiric treatment with clarithromycin plus azithromycin was established, and a punch biopsy was obtained from the lesion on the muscle procerus region. The biopsy showed a granulomatous infiltrate in the deep dermis and the hypodermis [Table/Fig-2a]. The granulomas were epithelioid, irregularly shaped, and without giant cells [Table/Fig-2b]. There was no central necrosis; instead, the epithelioid cells appeared admixed, and the center of the granuloma was occupied by an abscess [Table/Fig-2c]. Fungal forms were not identified after histochemical staining with Grocott and periodic-acid Schiff (PAS). Ziehl-Neelsen and Fite-Faraco stainings showed small amounts of acid-fast positive bacilli [Table/Fig-2d].



[Table/Fig-1]: Clinical appearance of the lesion, which is composed of a swollen, tender, erythematous plaque and confluent nodules **[Table/Fig-2a-d]:** The biopsy shows a deep dermal and hypodermal inflammatory granulomatous infiltrate (A) with epithelioid cells in the periphery (B) and abscessified central areas (C). Some acid-fast positive bacilli were identified with Fite-Faraco staining (D)

An investigation for the possible source of the infection was conducted. The infection was a unique case among all the patients of this specific dermatologist. The botulinum toxin vials were sterile and directly provided by the manufacturer. We did not identify any other cases of mycobacterial infection among other dermatological and cosmetic consultancies in the city that were supplied by the same manufacturer of the botulinum toxin A. The dermatologist confirmed that all the materials and instruments used by the (including syringes, gauzes, and anesthetics) were sterile and disposable. The patient admitted to having used some cosmetic facial creams on the areas of injection immediately after the procedure for several days. She was asked to bring these facial creams to the clinic, and some samples were sent for microbiological cultures with negative results. Therefore, we were not able to identify the source of infection in this case and have placed the botulinum toxin A as a possible etiology (Score 1 of Naranjo algorithm).

Due to the morphologic evidence of acid-fast bacilli, rifampicin was added to clarithromycin and azithromycin. The lesion cleared in 40 d, leaving residual postinflammatory pigmentation.

DISCUSSION

Non-tuberculosis mycobacteria (NTM) are usually acquired through environmental exposure rather than through person-to-person contact. NTM are ubiquitous and are mainly present in soil and water from rivers or lakes. However, the microorganism is resistant to the standard levels of chlorination; therefore, it can be found in tap water. The main mechanisms of infection are aerosol route, dust, water, ingestion, and inoculation through the skin. Even when exposure has occurred, the organisms are low in virulence, so local factors are usually needed for the infection to develop. The incubation period varies from several weeks to nearly one year and depends on the type of mycobacteria as well as the immune response of the individual.

Nearly all mycobacteria can infect the skin, but in developed countries *M. marinum* is the most common source of skin infection, followed by *M. abscessus*, *M. fortuitum*, and *M. chelonae*.

In recent years an increase in the incidence of NTM has been observed [1]. Although there is no solid explanation for this phenomenon, it has been at least partially attributed to the increasing development of the cosmetic and aesthetic dermatological industries. Cases have been reported following cutaneous surgery, acupuncture, breast

reconstruction, face lift, blepharoplasty, mesotherapy, epidural injection, liposuction, piercing, or tattooing.

The case presented could be related to the toxin and it is not necessarily iatrogenic. We have not found any previous cases related to cosmetic procedures with botulinum toxin A. The latter is a well-known botulinum neurotoxin produced by strains of *Clostridium botulinum*. There are several available botulinum neurotoxins; onabotulinumtoxin A is widely used. It has been commercialized under several branches under strict quality industrial control. Injections are usually administered with sterilized insulin-type syringes that are generally provided by the manufacturer. Therefore, mycobacteria may be accidentally introduced as a contaminant in any step during the procedure. For instance, antiseptics used to "sterilize" the injection site may be contaminated; mycobacterial infection may occur after contamination of benzalkonium chloride or glutaraldehyde. Tap water is another possible source of contamination.

Several cases of abscess due to mycobacterial infection after injections have been reported in India [2], China [3], and Thailand [4]. Muthusami et al., reported a study of 23 patients from India with chronic soft tissue infection caused by *M. fortuitum*, and in at least in 20 of these cases the route of infection was iatrogenic "through contaminated needles, syringes, drugs or instruments" [2]. Also, Camargo et al., reported a study of 232 patients in Colombia with cutaneous lesions due to iatrogenic infection by *M. abscessus* (formerly known as *M. chelonae* subsp. abscessus) [5]. The source in all patients was the same: subcutaneous injections of lidocaine given by a "bioenergetic practitioner" from contaminated capsules that had been refilled and reused [5]. Other sources include contaminated needles, metal objects, drug delivery systems, or marking solutions used in surgery. However, mycobacterial infection is rare with the use of disposable syringes, and it is mainly associated with the use of unapproved medications.

From a histopathological point of view, Rodriguez et al., presented a study [6] on 71 patients with lesions caused by *M. chelonae* infection that had previously been included in another report [5]. The most common histopathological presentation was abscesses surrounded by epithelioid and Langhans' giant cells (80% of the cases), while 15% of the cases involved abscesses with a discrete granulomatous component, and in 5% the granulomatous component was absent [5]. Also, Lee et al., found marked granulomatous inflammation in 86% of their biopsied cases [7]. Suppurative and mixed granulomas

were the most common [7]. One curious finding, which was observed by Camargo et al., in 82% of their cases, was well-defined, clear, round vacuolar spaces, some of which contained conglomerates of acid-fast bacilli. The authors interpreted such spaces as having a lipid origin [5].

Min et al., studied 25 patients diagnosed with cutaneous infection by mycobacteria, either tuberculous or NTM [8]. They compared the histopathological features identified in both groups. Tuberculoid granulomas were not identified in any case of NTM, and plasma cells were not a common finding in NTM cases. On the contrary, neutrophilic infiltrates and small vessel proliferation were more commonly found in cases of NTM infection. Min et al., found statistically significant differences ($p < 0.05$) between the two groups for the following features: neutrophil infiltration, interstitial granuloma, small vessel proliferation, and increased numbers of bacilli favored NTM infection, whereas giant cells, plasma cells, tuberculoid granulomas, and necrosis favored tuberculosis [8].

CONCLUSION

We report, to the best of our knowledge, the first case of cutaneous non-tuberculous mycobacteriosis secondary to the cosmetic injection of botulinum toxin A. However, we were not able to find the source of the contamination.

REFERENCES

- [1] Wentworth AB, Drage LA, Wengenack NL, Wilson JW, Lohse CM. Increased incidence of cutaneous nontuberculous mycobacterial infection, 1980 to 2009: a population-based study. *Mayo Clin Proc.* 2013;88:38-45.
- [2] Muthusami JC, Vyas FL, Mukundan U, Jesudason MR, Govil S, Jesudason SR. Mycobacterium fortuitum: an iatrogenic cause of soft tissue infection in surgery. *ANZ J Surg.* 2004;74:662-66.
- [3] Yuan J, Liu Y, Yang Z, Cai Y, Deng Z, Qin P, et al. Mycobacterium abscessus post-injection abscesses from extrinsic contamination of multiple-dose bottles of normal saline in a rural clinic. *Int J Infect Dis.* 2009;13:537-42.
- [4] Wongkitisophon P, Rattanakaemakorn P, Tanrattanakorn S, Vachiramon V. Cutaneous Mycobacterium abscessus Infection Associated with Mesotherapy Injection. *Case Rep Dermatol.* 2011;3:37-41.
- [5] Camargo D, Saad C, Ruiz F, Ramirez ME, Lineros M, Rodriguez G, et al. Iatrogenic outbreak of *M. chelonae* skin abscesses. *Epidemiol Infect.* 1996;117:113-19.
- [6] Rodriguez G, Ortegon M, Camargo D, Orozco LC. Iatrogenic Mycobacterium abscessus infection: histopathology of 71 patients. *Br J Dermatol.* 1997;137:214-18.
- [7] Lee WJ, Kang SM, Sung H, Won CH, Chang SE, Lee MW, et al. Non-tuberculous mycobacterial infections of the skin: a retrospective study of 29 cases. *J Dermatol.* 2010;37:965-72.
- [8] Min KW, Ko JY, Park CK. Histopathological spectrum of cutaneous tuberculosis and non-tuberculous mycobacterial infections. *J Cutan Pathol.* 2012;39:582-95.

PARTICULARS OF CONTRIBUTORS:

1. Consultant Dermatologist, Department of Pathology, Instituto Nacional de Ciencias Médicas y Nutrición Salvador Zubirán, Hospital Angeles Lomas, Centro Medico ABC, Mexico City, Mexico.
2. Dermatology, Private Practice.
3. Dermatopathologist, Department of Cellular Pathology, Hospital El Bierzo, Ponferrada, Spain.

NAME, ADDRESS, E-MAIL ID OF THE CORRESPONDING AUTHOR:

Dr. Angel Fernandez-Flores,
Servicio de Anatomía Patológica, Hospital El Bierzo, Medicos sin Fronteras 7, 24411, Ponferrada, Spain.
E-mail: dermatopathonline@gmail.com

FINANCIAL OR OTHER COMPETING INTERESTS: None.

Date of Submission: Oct 19, 2014

Date of Peer Review: Jan 20, 2015

Date of Acceptance: Jan 27, 2015

Date of Publishing: Apr 01, 2015